



Immediate Implant Loading After Unsuccessful Orthodontic Treatment: A Case Report

**Antônio Ednardo de Souza Filho ^{a++*},
Lucas de Araújo Albuquerque ^{a++},
Guilherme Salles Ottoboni ^{a†},
Calebe Lamonier de Oliveira Costa Paiva ^{a#†},
Júlio César Monteiro Barbosa ^{a†},
Joelson Pessoa Dantas ^{a++},
Pedro Teylon Paiva Muniz ^{a++},
Jamilly Vitória Souza Frota ^{a++},
Francisco Danilo Madeira Araújo ^{a++}
and Poliana Lima Bastos ^{a‡}**

^a Federal University of Ceará - Sobral Campus, Brazil.

Authors' contributions

This work was carried out in collaboration among all authors. Authors PLB, CLOCP and GSO designed the study and guided the research. The authors AESF, GSO and JCMB effectively participated in the clinical care. Authors PLB, AESF and JPD wrote the manuscript and carried out the translations. The authors PTPM, FDMA, JVSF and LAA adapted the article to the journal's standards. All authors read and approved the final manuscript.

Article Information

DOI: <https://doi.org/10.9734/acri/2025/v25i21084>

Open Peer Review History:

This journal follows the Advanced Open Peer Review policy. Identity of the Reviewers, Editor(s) and additional Reviewers, peer review comments, different versions of the manuscript, comments of the editors, etc are available here: <https://pr.sdiarticle5.com/review-history/130737>

⁺⁺ Student of the Dentistry Course;

[#] Master's Student of the Dentistry Course;

[†] Teacher of the Dentistry Course;

[‡] Go Up Training - Teacher of the Postgraduate Course;

*Corresponding author: Email: Ednardosouza1@gmail.com;

Cite as: Filho, Antônio Ednardo de Souza, Lucas de Araújo Albuquerque, Guilherme Salles Ottoboni, Calebe Lamonier de Oliveira Costa Paiva, Júlio César Monteiro Barbosa, Joelson Pessoa Dantas, Pedro Teylon Paiva Muniz, Jamilly Vitória Souza Frota, Francisco Danilo Madeira Araújo, and Poliana Lima Bastos. 2025. "Immediate Implant Loading After Unsuccessful Orthodontic Treatment: A Case Report". Archives of Current Research International 25 (2):253-58. <https://doi.org/10.9734/acri/2025/v25i21084>.

Case Report

Received: 06/12/2024

Accepted: 08/02/2025

Published: 11/02/2025

ABSTRACT

Objectives: The objective of this study is to describe a patient with a history of recent orthodontic treatment and who presented internal resorption and mobility in element 12.

Case Presentation: A 24-year-old female patient with a recent history of orthodontic treatment came to the dentist complaining of mobility in tooth 12. After a tomographic analysis, a large internal resorption was observed in tooth 12 and external resorption in teeth 13, 11, 21, 22 and 23, but without significant mobility. Therefore, it was decided to preserve the teeth that presented external resorptions, but without mobility, and extract tooth 12, due to its critical condition, and install an implant with immediate loading if the torque exceeded 35 N. The implant was placed with a torque of 60 N/cm².

Discussion: As is evident, one of the greatest advantages of combining the two techniques is the reduction in treatment time, maintenance of the morphology of soft and hard tissues, in addition to obtaining immediate aesthetics, which contributes to good acceptance of the technique by the patients treated.

Conclusion: In this way, it was possible to restore function, aesthetics and quality of life to the patient.

Keywords: *Odontology; dental implant; immediate loading, surgical interventions.*

1. INTRODUCTION

An individual's image is crucial to making them feel good physically and socially, as well as motivated to face daily challenges. And for dentists, it is extremely important to consider all functional, aesthetic and psychological aspects, as they are all directly associated with the patient's health (Oliveira, et al., 2020).

Orthodontic treatment aims to correct the position of teeth and jaw bones and uses biomechanical forces as principles to achieve its results. However, this therapy can cause a pathological condition when used incorrectly, such as root resorption, which is caused by a local inflammatory condition caused by excessive force on the dental tissues during orthodontic movement, causing impairment and condemnation of the affected tooth, requiring rehabilitation interventions to treat this condition (Ferlin, et al., 2014).

In view of this, immediate implants, which are characterized by being installed after extraction, can be used in these cases of treatment of condemned teeth, since the technique has the advantages of maintaining the marginal bone ridges, reducing treatment time and the number of surgical interventions, which are fundamental

for rehabilitation treatment. In addition, this method aims to increase the aesthetic potential, which allows the maintenance of the architecture of the bone tissue and when used in conjunction with soft and hard tissue grafts or even with bone replacement biomaterials, it maximizes the results (Porto, 2022).

In this sense, it is possible to associate the immediate implant technique with the immediate loading technique, as it allows the prosthetic crown to receive masticatory load after the surgical stage, without a waiting period for the osseointegration process. Thus, the great advantage of performing immediate loading is the immediate return of the aesthetics and function of the region, in addition to promoting better healing of the soft tissues, preventing the use of a removable provisional prosthesis, avoiding a second surgical procedure, causing less patient morbidity and reducing damage to the adjacent gingival aesthetics. However, some factors are necessary to be able to adhere to the technique, such as good bone quality and promotion of primary stability, which is achieved when the implant is locked with a torque of at least 35 N/cm², preventing micromovements greater than 150 µm of the implant interface with the supporting bone tissue (Lacerda, et al., 2023, Jassé, et al., 2010).

The objective of this study is to describe a clinical case of rehabilitation of a lateral incisor that was affected by external root resorption after the use of an orthodontic appliance, in which the implant and the provisional implant were installed in the same surgical procedure, with immediate loading.

This work was approved by the Research Ethics Committee of the Vale do Acaraú State University (Number: 4,138,242).

2. CASE PRESENTATION

A 24-year-old female patient came to the dental clinic complaining of mobility in tooth 12. During the anamnesis, the patient reported having recently completed orthodontic therapy. The tomographic analysis revealed extensive internal resorption with pulp involvement in tooth 12, in addition to resorptions in teeth 13, 11, 21, 22, and 23 (Fig. 1). Therefore, after clinical evaluation, it was decided to perform tooth extraction and implant installation in the region of tooth 12, and to monitor the other teeth, as they did not present mobility.

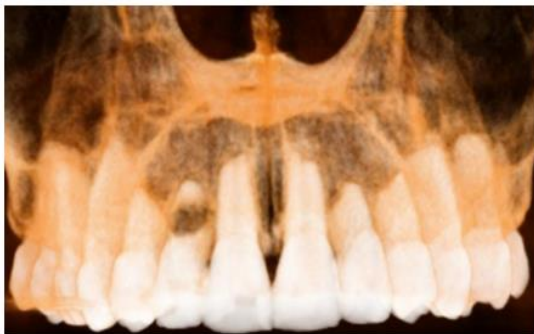

Fig. 1. Initial tomography

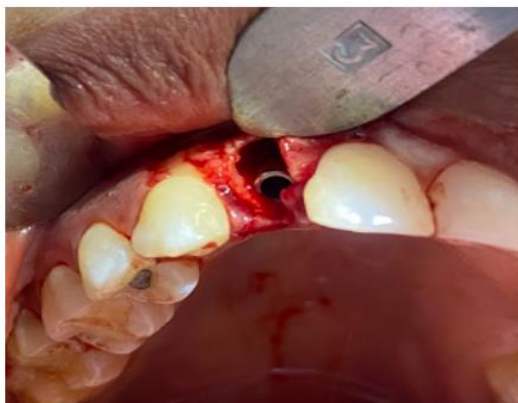

Fig. 2. Implant Installed

In the preoperative period, an impression of the arches was taken to create a surgical guide. The implant installed was the Indexed Morse Taper Wayfit (DSP®, Paraná, Brazil) measuring 3.5 x 15.0 mm, with a torque of 60 N/cm² (Fig. 2), enabling the installation of the provisional and activation of the occlusal load.

After installation of the prosthetic component, 0.5 g of bovine bone graft (Lumina-Bone Criteria®, São Paulo, Brazil) was inserted to fill the empty spaces between the implant and the remaining bone (Fig. 3) and the peri-implant soft tissues were sutured.

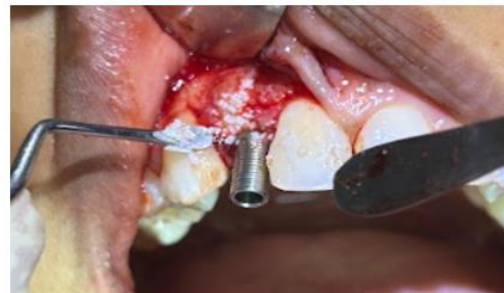

Fig. 3. Installation of the prosthetic component and insertion of bone graft

To make the provisional crown, the titanium abutment served as an anchor for adapting the provisional prosthetic crown. After fixing the crown to the titanium abutment using acrylic resin, finishing and polishing were performed (Fig. 4).

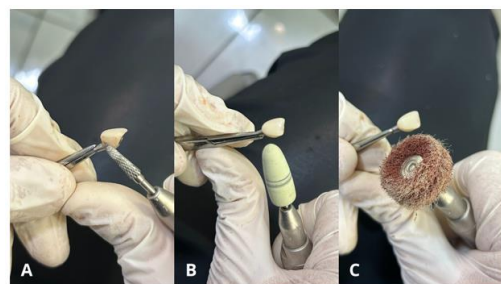


Fig. 4. Finishing and polishing of the provisional crown

Finally, the abutment was fixed (torque of 10 N/cm²), and then the prosthetic screw was protected and occlusal adjustment was performed in order to distribute the occlusal loads evenly, to avoid overloading the installed implant. This case is being monitored for subsequent installation of the definitive crown (Fig. 5).

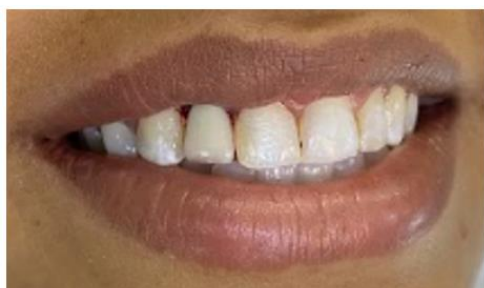

Fig. 5. Final result

3. DISCUSSION

Immediate implant treatment with immediate loading in condemned teeth has been a practice with predictable success in Dentistry. Study evaluated immediate implant placement and immediate restoration with a single crown in the anterior maxillary region; they reported 626 implants with a success rate of 97.96% and a survival rate of 98.25% (Weigl & Strangio, 2016, Kan, et al., 2018).

As seen in the clinical case, one of the main advantages of combining the two techniques is the reduction in treatment time, preservation of the morphology of soft and hard tissues and establishment of immediate aesthetics, which makes the technique well accepted by the patients treated, corroborating other studies in the literature (Porto, 2022, Cipriani, 2019, Calderon, et al., 2024, Bineviciute & Juodzbals, 2024, Shamir, et al., 2022).

However, some prerequisites are necessary to achieve satisfactory results, such as minimally traumatic extraction, correct three-dimensional position of the implant, adequate management of soft and hard tissues, evaluation of the morphology of the gap (implant and vestibular bone plate) and primary stability (Kan, et al., 2018, Elaskary, et al., 2024, Atri & Nokar, 2024).

In the same way, in relation to the anatomical aspects of the implant area, importance should be given mainly to the quantity and quality of bone available, and these are fundamental to obtain primary stability and consequent success of the implant-supported prosthesis, there being a relationship between primary stability and bone density (Miranda, 2022, Monezi, et al., 2019, Baek, et al., 2023). Both parameters were taken into consideration during the patient's treatment.

Seeking to understand the impact on the quality of life of patients who underwent implant rehabilitation with immediate loading, a study evaluated the degree of satisfaction and quality of life of patients rehabilitated with Osseo integrated implants subjected to immediate loading after an average time of 2 and a half years after the installation of the prostheses. A high level of general satisfaction was found among the individuals, resulting in good quality of life related to oral health. The patients were satisfied with the final result of their respective rehabilitations (Baschiroto, 2013, Castro, et al., 2010). The study also demonstrated that there was an improvement in phonetics, aesthetics and masticatory function, in addition to safety and confidence.

Another prospective cohort study also sought to understand the quality of life and mechanical and biological complications of patients who were treated with partial or single maxillary provisional rehabilitations supported by implants with immediate loading. The study included 35 patients with 40 prostheses supported by 60 implants. The results of the present study indicated a low percentage of patients affected by early mechanical (13.3%) or biological (5%) complications and a significant improvement in the quality of life of the treated patients (Sanchez-Torres, et al., 2024, Consolaro, 2011), exactly what was observed in this case report.

4. CONCLUSIONS

It was concluded that the technique of immediate implants with immediate loading, after unsatisfactory orthodontic treatment, is a good choice, as it optimizes treatment time and restores the patient's aesthetics and function. Finally, more in-depth studies with a greater number of clinical cases are important to consolidate the success of the treatment.

CONSENT

As per international standards or university standards, patient(s) written consent has been collected and preserved by the author(s).

ETHICAL APPROVAL

This clinical case is part of a clinical research approved by the Research Ethics Committee of the Vale do Acaraú State University (NUMBER: 4,138,242).

DISCLAIMER (ARTIFICIAL INTELLIGENCE)

Author(s) hereby declare that NO generative AI technologies such as Large Language Models (ChatGPT, COPILOT, etc) and text-to-image generators have been used during writing or editing of this manuscript.

ACKNOWLEDGEMENTS

Thanks to the educational institutions involved, Federal University of Ceará - Sobral Campus, Brazil and Go Up training.

Thanks to the Criteria ® for the donation of the bovine bone graft.

Thanks to the DSP ® donation of the implant and the component for the temporary prosthetic crown.

COMPETING INTERESTS

Authors have declared that no competing interests exist.

REFERENCES

- Atri, F., & Nokar, K. (2024). Prosthetic soft tissue management in esthetic implant restorations, part I: Presurgical planning, implant placement, and restoration timing. *The Narrative Review. Clinical and Experimental Medical Research*, 10(6), e900.
- Baek, Y. W., Lim, Y. J., & Kim, B. (2023). Comparison of implant surgery methods of cortical tapping and cortical widening in bone of various density: A three-dimensional finite element study. *Materials (Basel, Switzerland)*, 16(8), 3261.
- Baschiroto, T. V. (2013). Assessment of the degree of satisfaction and quality of life of patients rehabilitated with osseointegrated implants subjected to immediate loading. *Federal University of Santa Catarina*.
- Bineviciute, Z., & Juodzbals, G. (2024). Attitudes of oral surgeons and periodontists towards the positioning of immediate dental implants. *Journal of Oral & Maxillofacial Research*, 15(2), e3.
- Calderon, I., Alvez-Temoche, D., Espinoza-Carhuancha, F., Mendoza, R., Mauricio, F., & Mayta-Tovalino, F. (2024). Immediate loaded post-extraction implant and connective graft-guided bone regeneration: A case report. *Odvotos - International Journal of Dental Sciences*, 26(3), 38–45.
- Castro, L. M. S., et al. (2010). Assessment of the quality of life of patients rehabilitated with osseointegrated implants subjected to immediate loading: Longitudinal study. *Dental Press Journal of Periodontics and Implantology*, 4(2), 74–82.
- Cipriani, P. P. (2019). The challenge of immediate dental implant placement in an aesthetic region: A literature review. *University of Caxias do Sul*.
- Consolaro, A. (2011). The concept of dental resorptions or dental resorptions are not multifactorial, nor complex, controversial or polemic! *Dental Press Journal of Orthodontics*, 16(4), 19–24.
- Elaskary, A., Thabet, A., Hussin, M., & Radi, I. A. (2024). Soft and hard tissue evaluation for vestibular socket therapy of immediately placed implants in infected and noninfected sockets: A 1-year prospective cohort study. *BMC Oral Health*, 24(1), 1190.
- Ferlin, C. R., et al. (2014). Occurrence of root resorption in orthodontic treatment: Critical review of the literature. *Araçatuba Dental Journal*, 37–40.
- Jassé, F. F., et al. (2010). Immediate loading of single tooth implants: Literature review. *UNOPAR Scientific Biological and Health Sciences*, 12(1), 35–38.
- Kan, J. Y. K., Rungcharassaeng, K., Deflorian, M., Weinstein, T., Wang, H. L., & Testori, T. (2018). Immediate implant placement and provisionalization of single maxillary anterior implants. *Periodontology 2000*, 77(1), 197–212.
- Lacerda, J., Cardenas, A. M. C., Vançan, R. N., & Santos, A. M. (2023). Immediate loading on implants in the aesthetic area: Literature review. *Brazilian Journal of Implantology and Health Sciences*, 5(4), 03–26.
- Miranda, A. C. de. (2022). Immediate loading on anterior teeth: Literature review. *UNDB University Center*.
- Monezi, L. L. de L., Matos, E. M. C., Corrêa, R. C. de M., & Cavalcanti, T. C. (2019). Immediate implants: A literature review. *Electronic Journal Health Collection*, (30), e1037.
- Oliveira, G. S., Gusmão, Y. G., Nunes, F. M., Oliveira, I. S., Cangussu, L. S., & Gonçalves, M. C. (2020). Association between aesthetic dentistry and self-

- esteem. *Electronic Journal of Dental Collection*, 1, e3892.
- Porto, K. B. (2022). Advantages and disadvantages of installing immediate implants post-extraction. *FACSETE*.
- Sanchez-Torres, A., Moragon-Rodríguez, M., Agirre-Vitores, A., Cercadillo-Ibarguren, I., Figueiredo, R., & Valmaseda-Castellón, E. (2024). Early complications and quality of life in patients with immediately loaded implant-supported maxillary partial rehabilitations: A prospective cohort study. *Oral Medicine, Oral Pathology and Oral Surgery*, 29(2), e172–e179.
- Shamir, R., Daugela, P., & Juodzbaly, G. (2022). Comparison of classifications and indexes for extraction socket and implant-supported restoration in the aesthetic zone: A systematic review. *Journal of Oral & Maxillofacial Research*, 13(2), e1.
- Weigl, P., & Strangio, A. (2016). The impact of immediately placed and restored single-tooth implants on hard and soft tissues in the anterior maxilla. *European Journal of Oral Implantology*, 9(Suppl 1), S89–S106.

Disclaimer/Publisher's Note: The statements, opinions and data contained in all publications are solely those of the individual author(s) and contributor(s) and not of the publisher and/or the editor(s). This publisher and/or the editor(s) disclaim responsibility for any injury to people or property resulting from any ideas, methods, instructions or products referred to in the content.

© Copyright (2025): Author(s). The licensee is the journal publisher. This is an Open Access article distributed under the terms of the Creative Commons Attribution License (<http://creativecommons.org/licenses/by/4.0>), which permits unrestricted use, distribution, and reproduction in any medium, provided the original work is properly cited.

Peer-review history:

The peer review history for this paper can be accessed here:

<https://pr.sdiarticle5.com/review-history/130737>